

# Anatomy and disorders of the coccyx

## CHAPTER CONTENTS

<b>Anatomy of the coccyx</b> . . . . .	<b>611</b>
<b>Disorders of the coccyx</b> . . . . .	<b>611</b>
Referred coccygodynia . . . . .	611
Local coccygodynia . . . . .	611
Psychogenic coccygodynia . . . . .	613

## Anatomy of the coccyx

The coccyx is formed by fusion of four rudimentary vertebrae. The first coccygeal vertebra has a base for articulation with the apex of the sacrum and two cornua (cornua coccygea) that are usually large enough to articulate with the cornua sacralia. The sacrococcygeal joint is a true joint with a joint capsule and ligaments. Other ligaments covering the posterior aspect of the coccyx are the posterior intercoccygeal ligaments. The gluteus maximus partly inserts at the dorsolateral aspect of the coccyx via its coccygeal fibres (Fig. 44.1).

The coccyx and overlying skin are innervated via the dorsal rami of S4 and S5.

## Disorders of the coccyx

Usually, coccygeal pain results from a local lesion, but referred coccygodynia is possible and psychogenic pain also occurs.

### Referred coccygodynia

It is well known that coccygodynia can arise from a lumbar disc lesion, usually as the result of extrasegmental reference.<sup>1</sup> Coccygodynia may also arise from irritation of lower pelvic structures (neoplasms of rectum or prostate).<sup>2</sup> The history and clinical examination can easily distinguish referred pain from a

local disorder. In referred coccygodynia from a disc lesion, pain arises not only during sitting but also during lumbar movements. Coughing is also painful. Physical examination additionally shows pain during lumbar movements, and straight leg raising often increases the discomfort. However, palpation does not assist in diagnosis because local tenderness is to be expected, whichever variety of coccygodynia is present. Tumours or other causes of inflammation affecting the sacrum should be suspected if the pain is not relieved by lying down or if there is nocturnal discomfort. In case of doubt, epidural local anaesthesia can be useful.

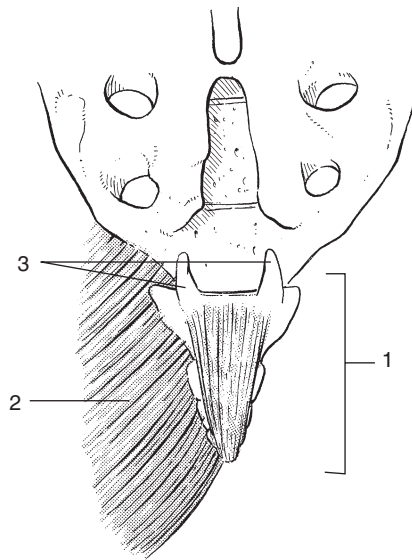
### Local coccygodynia

True coccygodynia nearly always affects women and the most common cause is traumatic. Usually, a direct contusion during a fall in the half-sitting position is responsible. Because the coccyx usually lies 2 cm above the two ischial tuberosities it can only be contused when the body is tilted backwards during a fall on the buttocks. Alternatively, in a fall onto a narrow object, the force may strike the coccyx rather than the ischial tuberosities.

In 'idiopathic' coccygodynia, no particular injury is noted. It has been suggested that certain anatomical variations of the coccyx predispose to repeated microtraumas, which then cause chronic irritation. A coccyx with a sharp forward angle seems to be more prone to painful stretching.<sup>3</sup>

Childbirth also causes injury sometimes and postpartum coccygodynia is a well-recognized entity.

Coccygodynia is related to sitting. Pain is felt at the coccyx only and does not spread in any direction. Sitting on a hard surface or with the buttocks over the border of the chair relieves the pain. Lumbar movements, standing and lying down do not provoke the pain. Coughing and sneezing is painless but defecation sometimes hurts. As a rule, walking is painless except when the coccygeal fibres of the gluteus maximus muscle are involved.



**Fig 44.1** • The coccyx (1) and its articulation with the sacrum; the insertion of the gluteus maximus (2); the two cornua (3) and the intercoccygeal ligaments.

The routine clinical examination of the lumbar spine, sacroiliac joints and hips will be found to be completely normal. Palpation will reveal a localized tender area. As already mentioned, tenderness is also present in referred and psychogenic coccygodynia, so the diagnosis should be made before palpation starts.

Palpation starts at mid-sacrum and four types of coccygodynia may be found:<sup>1</sup>

- Contusion of the tip of the coccyx and the immediate surrounding tissue. This is the most common type.
- Sprain of the posterior intercoccygeal ligaments.
- Sprain of the sacrococcygeal joint.
- Irritation of the coccygeal fibres of the gluteus maximus muscle. In this condition the pain is unilateral and may spread slightly to one buttock. Occasionally the patient complains that walking is uncomfortable.

## Treatment

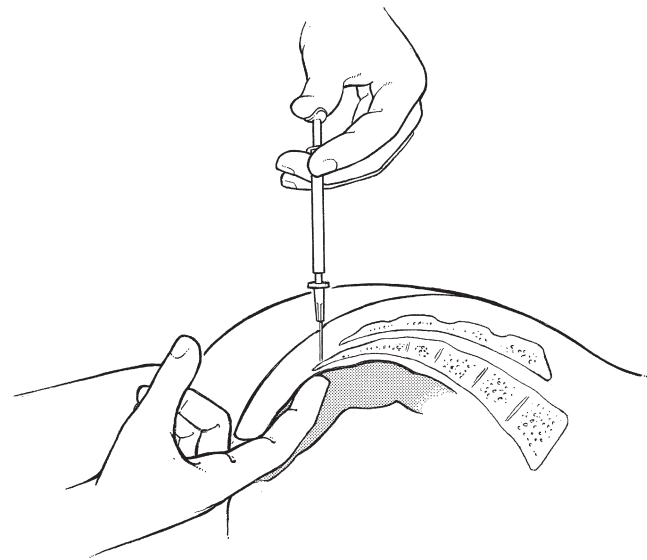
Apart from seating modifications that transfer the weight to the ischia, treatment may consist of deep transverse friction, steroid infiltrations or surgery.

### Deep transverse friction

When applied to the affected ligaments, this is very often quickly effective. Six to eight sessions two or three times a week usually suffice, except in contusion of the tip of the coccyx, where infiltration of a local steroid usually affords better and quicker results.

### Technique

The patient lies prone with a pillow under the pelvis. The legs are slightly abducted and internally rotated. The physiotherapist sits next to the patient and places one thumb on the affected spot. If the lesion is at the sacrococcygeal or dorsal



**Fig 44.2** • Steroid infiltration of the coccyx.

intercoccygeal ligaments, friction is given using alternating, up-and-down movements of the thumb. If the lesion lies at the insertion of the gluteal fibres, the thumb should be pressed deeply between the muscle and the lateral border of the coccyx. Friction is then given by drawing the thumb up and down along the edge of the bone.

### Steroid infiltration

This can be done if the lesion lies at the tip of the coccyx or when deep friction does not succeed. The injection is usually very effective, but if the patient does not take preventive measures in the form of seating modifications, then relapses may be encountered.<sup>4</sup>

### Technique

The patient lies prone on the couch, the pelvis slightly tilted and the legs internally rotated. The tenderness is carefully sought. Sometimes it is necessary to perform rectal palpation (Fig. 44.2). The coccyx is then pressed between the index finger and the thumb. In this position the injection can be given precisely and without fear of penetrating the rectum. This precaution is particularly appropriate if the sacrococcygeal joint or the apex of the coccyx is infiltrated.

A 1 mL tuberculin syringe, filled with 10 mg of triamcinolone, is fitted to a thin 2 cm needle. After careful preparation of the skin, the needle is introduced at the localized spot until it hits bone. By half-withdrawing the needle and reinserting it at a slightly different angle, the entire lesion is infiltrated with a series of tiny neighbouring punctures. The palpating thumb and index finger feel exactly where each droplet is deposited.

After injection, the coccyx remains sore for a few days before the symptoms abate. The patient is re-examined after 2 weeks. A second infiltration is made if some residual tenderness remains.

If the condition recurs frequently, the steroid solution should be replaced by two infiltrations of sclerosant solution (1.5 mL of sclerosant and 0.5 mL of lidocaine 2%). Although

very painful during the days following the injections, it usually affords permanent results.

### *Coccygectomy*

This is only considered in intractable incapacitating pain persisting in spite of adequate conservative treatment. However, the operation is very rarely indicated and the results are far from good.<sup>5,6</sup> Furthermore a high incidence of Gram-negative infection following coccygectomy has been reported.<sup>7</sup>

## Psychogenic coccygodynia

---





Coccygeal pain may be of psychogenic origin. Because the diagnosis is usually made by eliciting tenderness, the

elimination of a psychogenic case is extremely important. Usually the history helps: genuine local coccygodynia does not spread and psychogenic pain is usually vague and radiates in various (impossible) directions. In local coccygodynia, lumbar or hip movements do not elicit pain, whereas they all hurt in a psychogenic case. If suspicion of psychogenic coccygodynia arises, the patient must be given enough freedom during the history and functional examination for contradictions to emerge (see online chapter *Psychogenic pain*).



Access the complete reference list online at [www.orthopaedicmedicineonline.com](http://www.orthopaedicmedicineonline.com)

## References

1. Cyriax JH. *Textbook of Orthopaedic Medicine*. vol I, 8th ed. London: Baillière Tindall; 1982. p. 302.
2. Traycoff RB, Crayton H, Dodson R. Sacrococcygeal pain syndromes: diagnosis and treatment. *Orthopedics* 1989;**12**(16): 1373–7. 
3. Postachini F, Massobrio M. Idiopathic coccygodynia. Analysis of fifty-one operative cases and a radiographic study of the normal coccyx. *J Bone Joint Surg* 1983;**65**: 1116–24. 
4. Kersey PJ. Non-operative management of coccygodynia. *Lancet* 1980;**1**:318. 
5. Beinhaker NA, Ranawat CS, Marchisello P. Coccygodynia: surgical versus conservative treatment. *Orthop Trans* 1977;**1**:162.
6. Pyper JB. Excision of the coccyx for coccygodynia. A study of the results in twenty-eight cases. *J Bone Joint Surg* 1957;**39B**:733–7. 
7. Bayne O, Bateman JE, Cameron HU. Influence of etiology on the results of coccygectomy. *Clin Orthop* 1984;**190**: 266–72. 